



*Centre of Studies for
Restorative Dentistry*

(COLLOQUIUM 2012)

ENDODONTIC EMERGENCIES

Nik Zarina Nik Mahmood

OUTLINES

- DEFINITION
- CATEGORIES OF EMERGENCIES
- MANAGEMENT OF EACH CATEGORY

- **OBJECTIVES:**
 - Can manage endo emergency cases independantly
 - When to refer to endodontist

ENDODONTIC EMERGENCIES

- **Endodontic** is a Greek word
- *Endo*: "inside" and *odont*: "tooth"

- **Emergency** means condition require an unschedule visit with immediate diagnosis and treatment

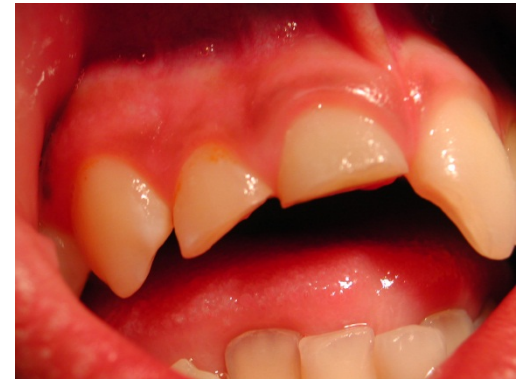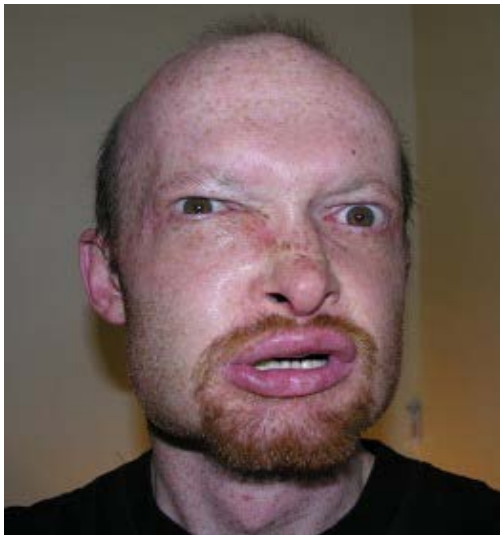
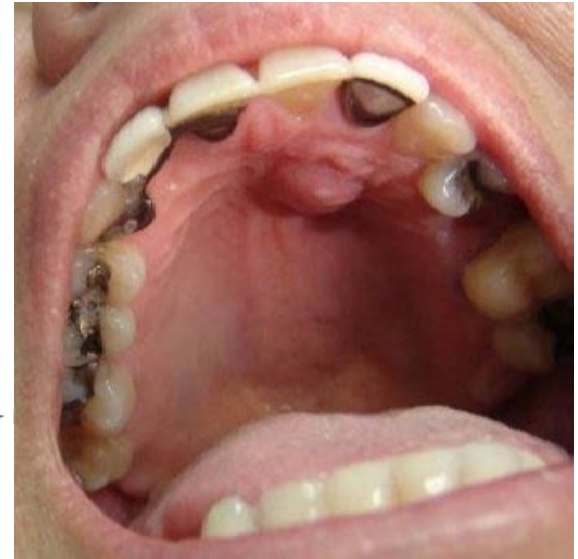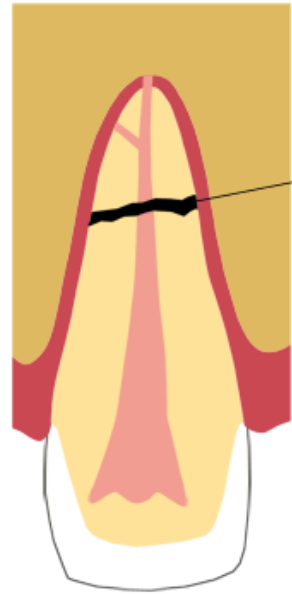
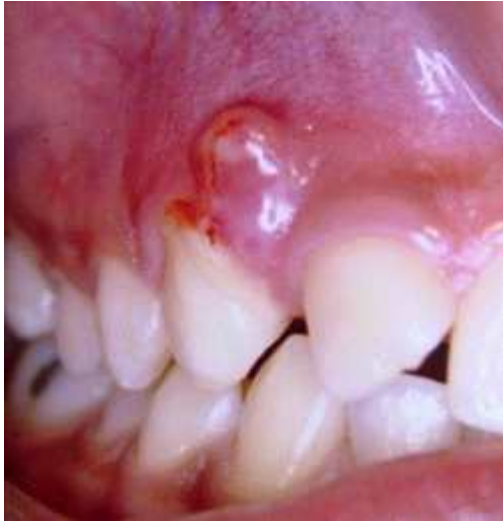“It’s all about the pain and swelling”



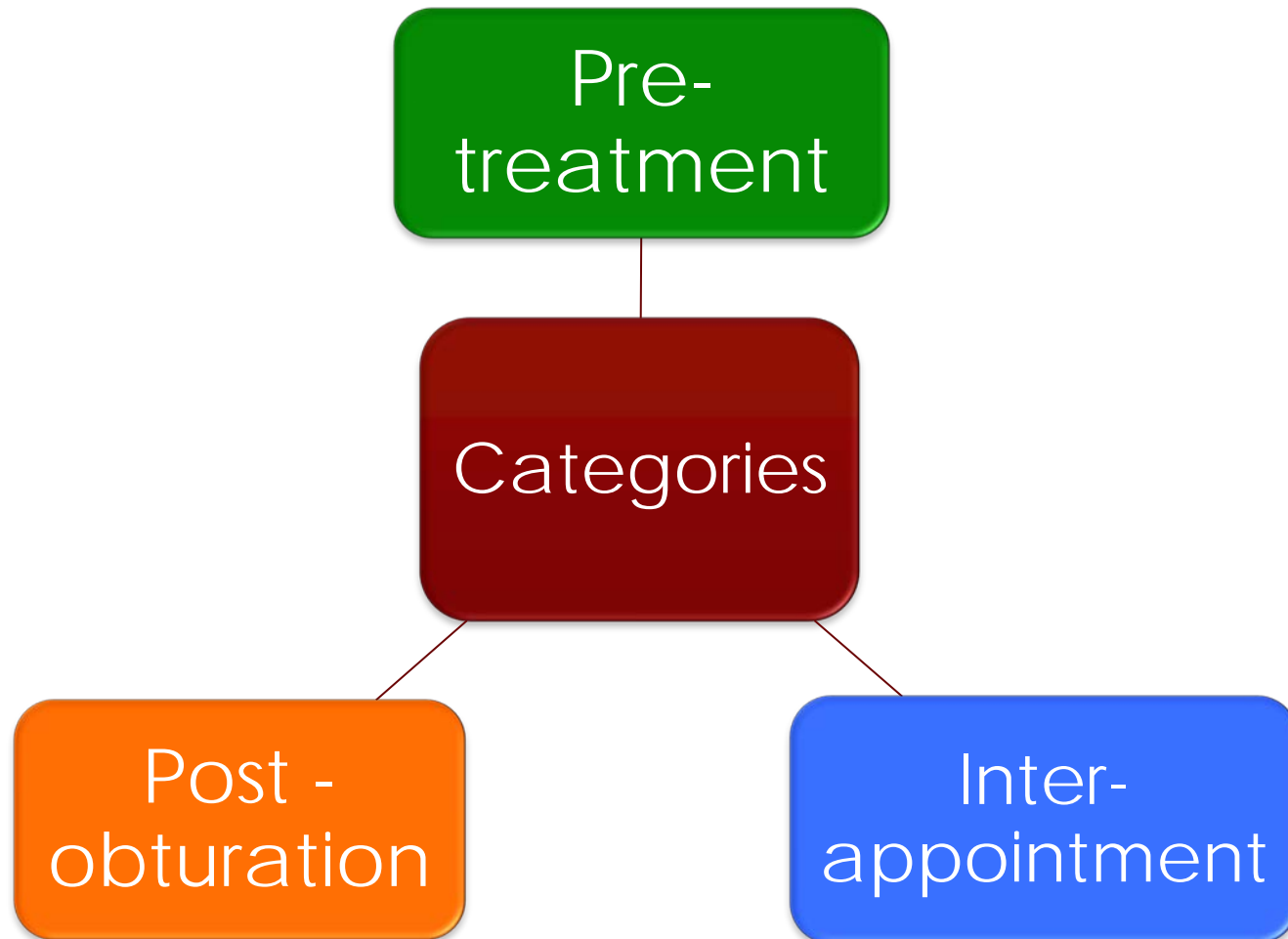
Endodontic Emergencies

- Caused by pulp pathosis or periradicular tissues
- Traumatic injuries

EMERGENCIES



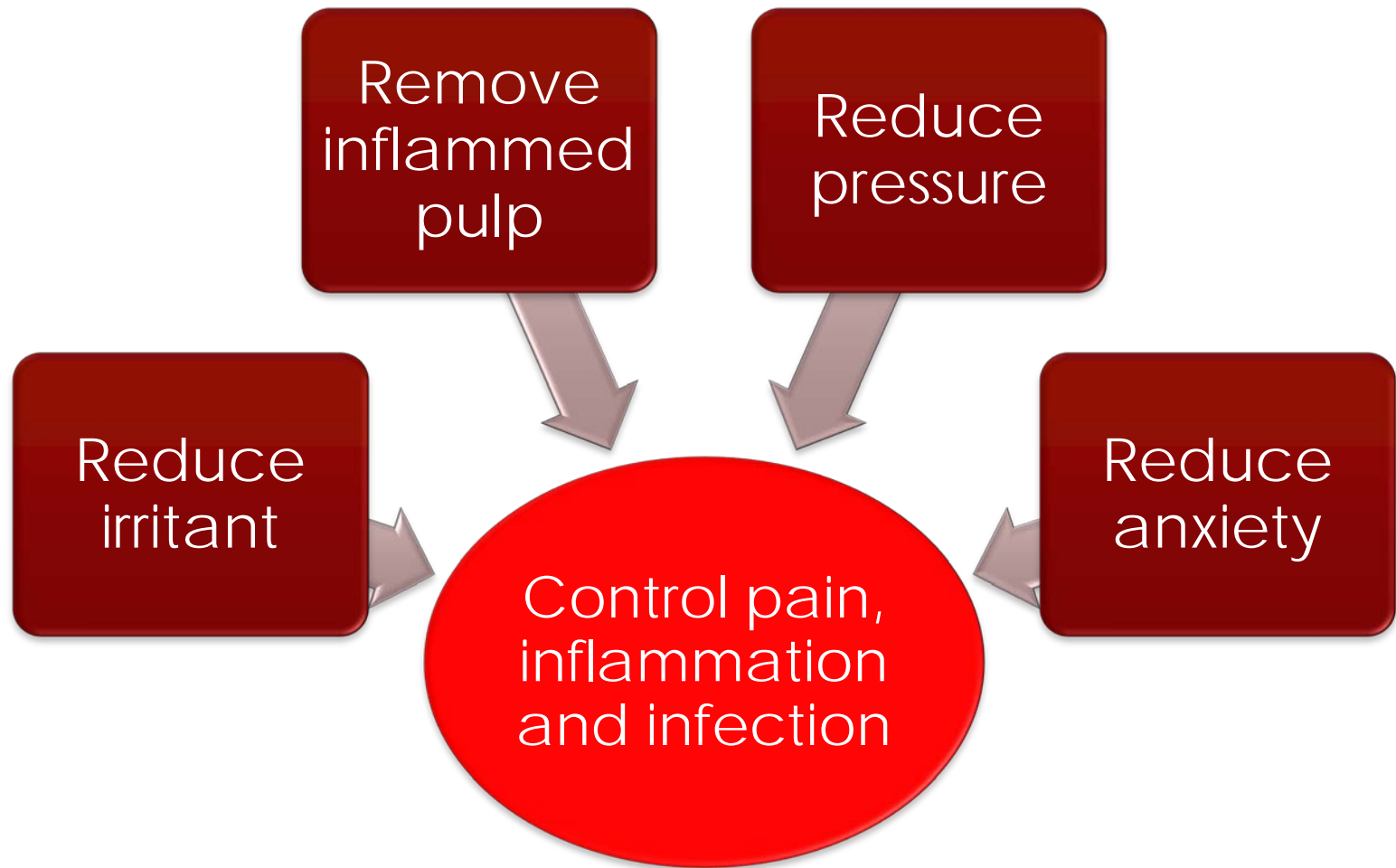
Endodontic Emergencies





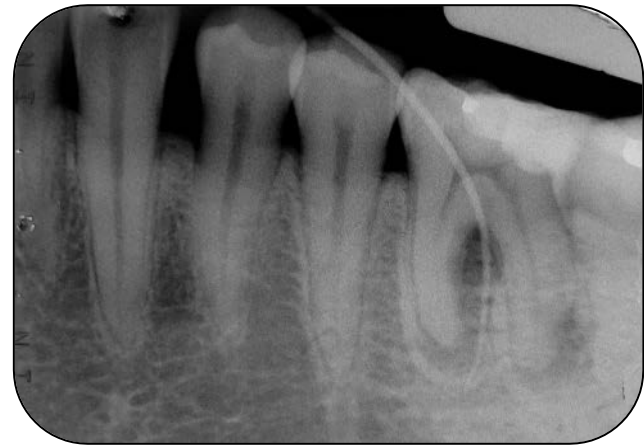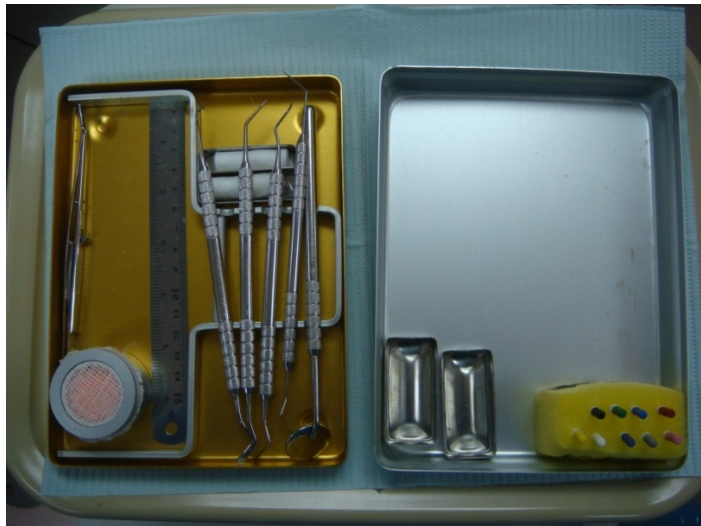Immediate treatment and
diagnosis are crucial!

General Guidelines

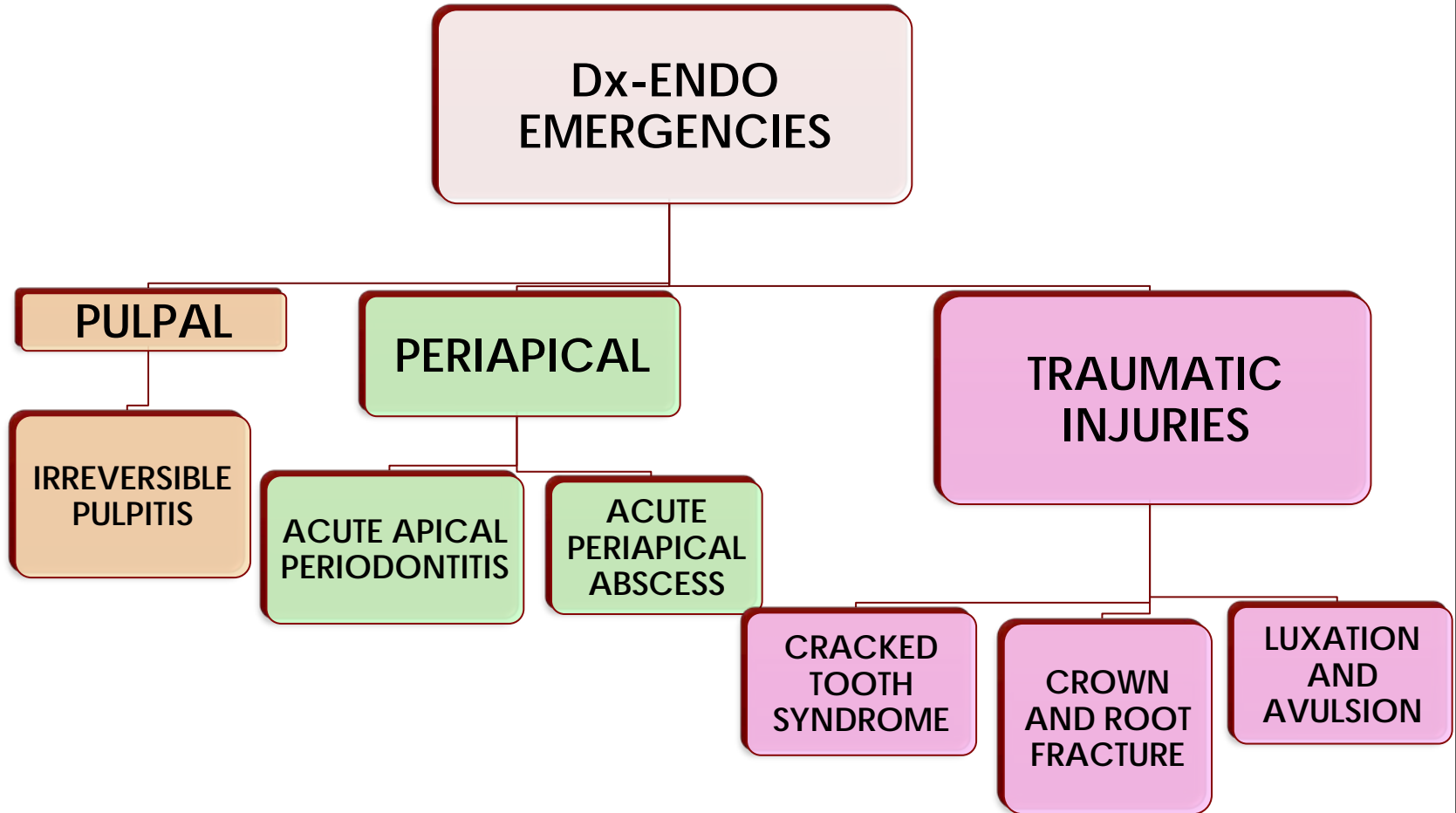


Diagnosis

- History taking
- Clinical examination
- Special investigations
- Diagnosis
- Treatment Planning



PRE-TREATMENT



Mx of Irreversible Pulpitis

○ Preferred treatment:

- Pulpectomy- total removal of vital pulp- **RD compulsory**

▪ Alternatives-

- partial pulpectomy or pulpotomy
- Antibiotic paste(endopaste)
- Root canal treatment ASAP



Patient with rubber dam placed.
Note the protective goggles in place.

Irreversible pulpitis

WITH ACUTE APICAL PERIODONTITIS-


-Relieved occlusion

-Mild analgesic

ANTIBIOTICS NOT INDICATED

Self limiting condition

Periapical abscess

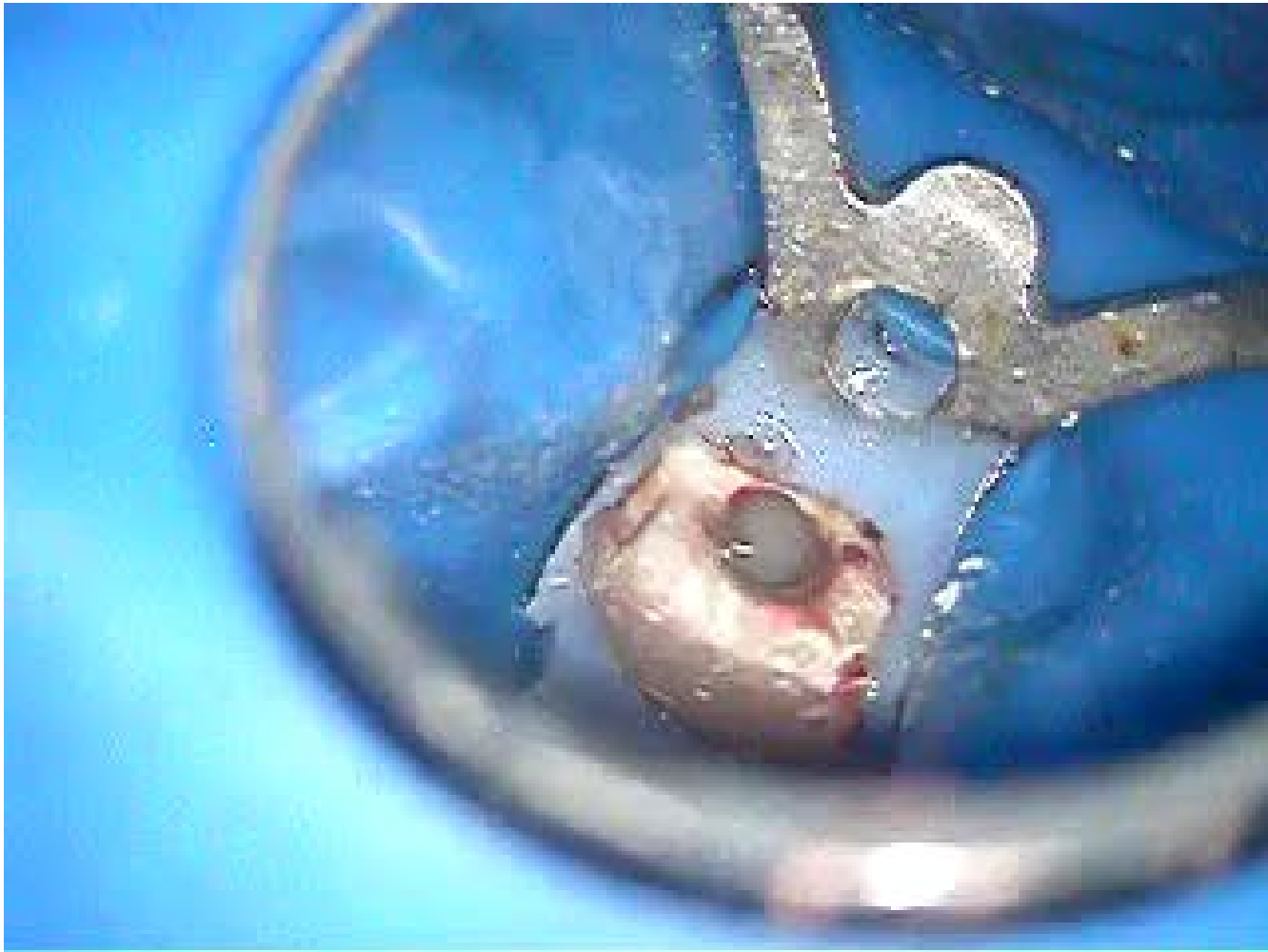


Drainage or venting pressure helps effect relief!!!

Drainage:

- Through the tooth
- Through the soft tissue
- Through the bone

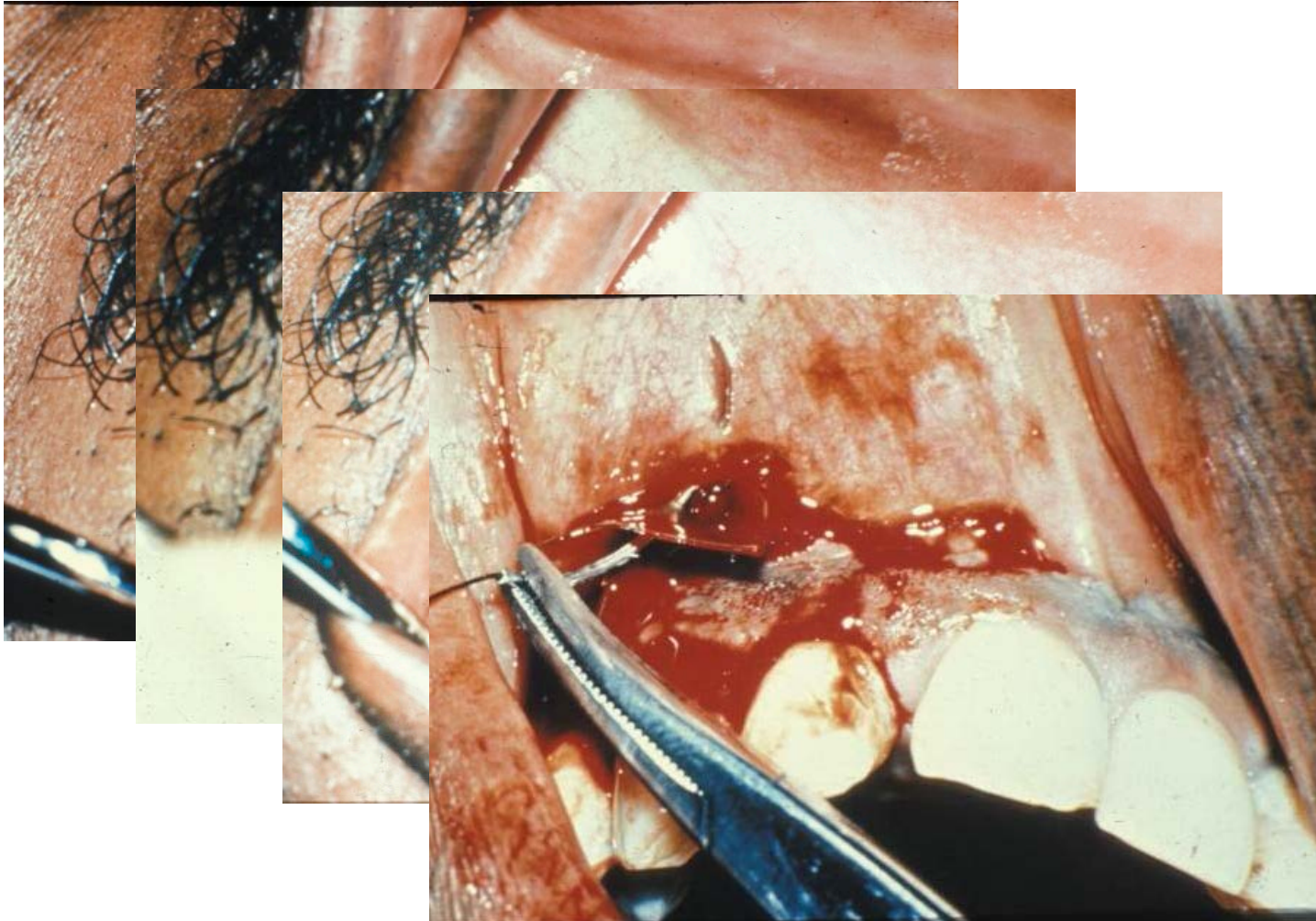
Drainage through the tooth



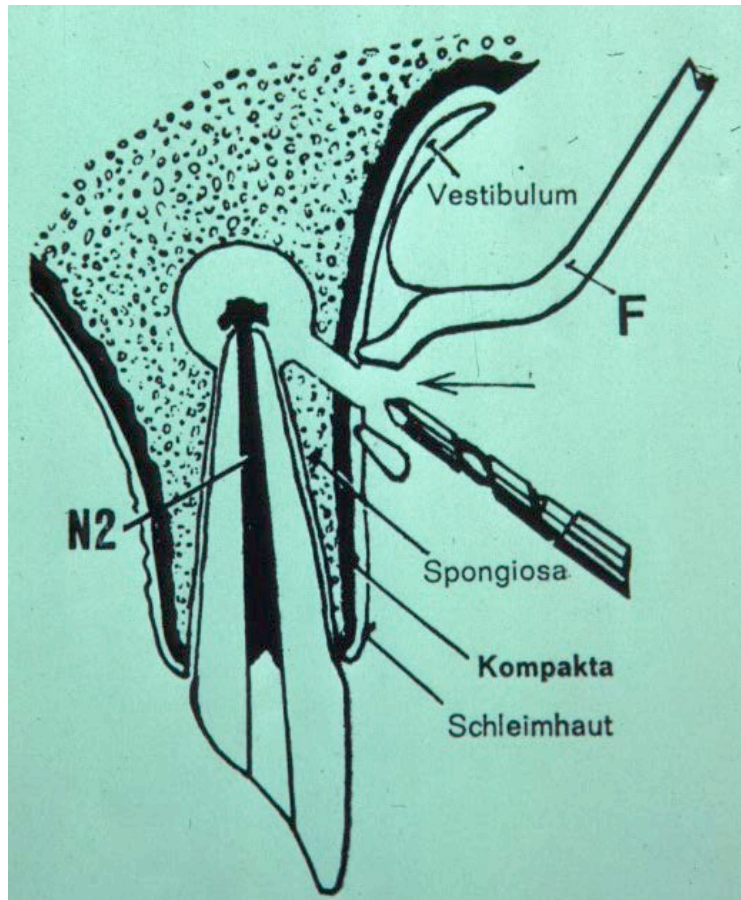
Acute Periapical Abscess

- Canal debridement (NaOCL 2.5% irrigation)
- Require penetration of small files# 15, #20
- encourage drainage to apical followed by $\text{Ca}(\text{OH})_2$ or endopaste placement dressing " **DO NOT OPEN DRAIN**"
- Relieved occlusion if tooth is extruded

Drainage Through Soft Tissue



Drainage through the bone

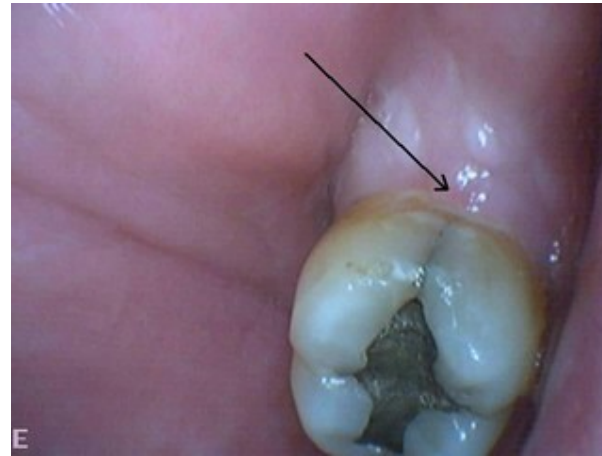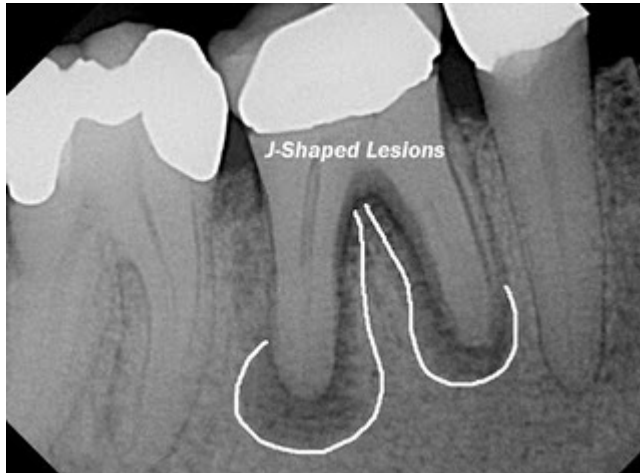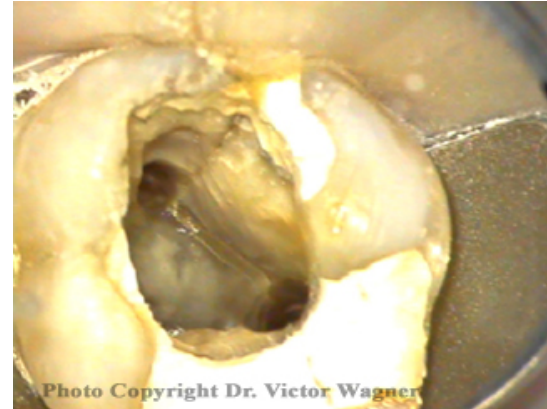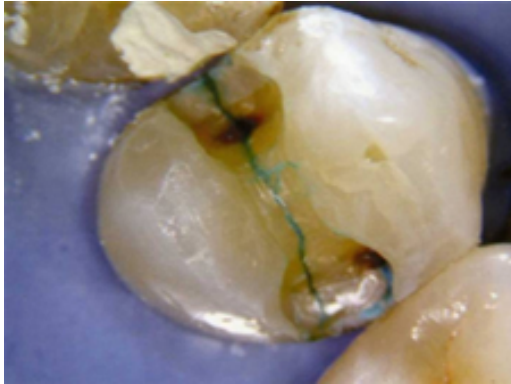


Trephination



TRAUMATIC INJURIES

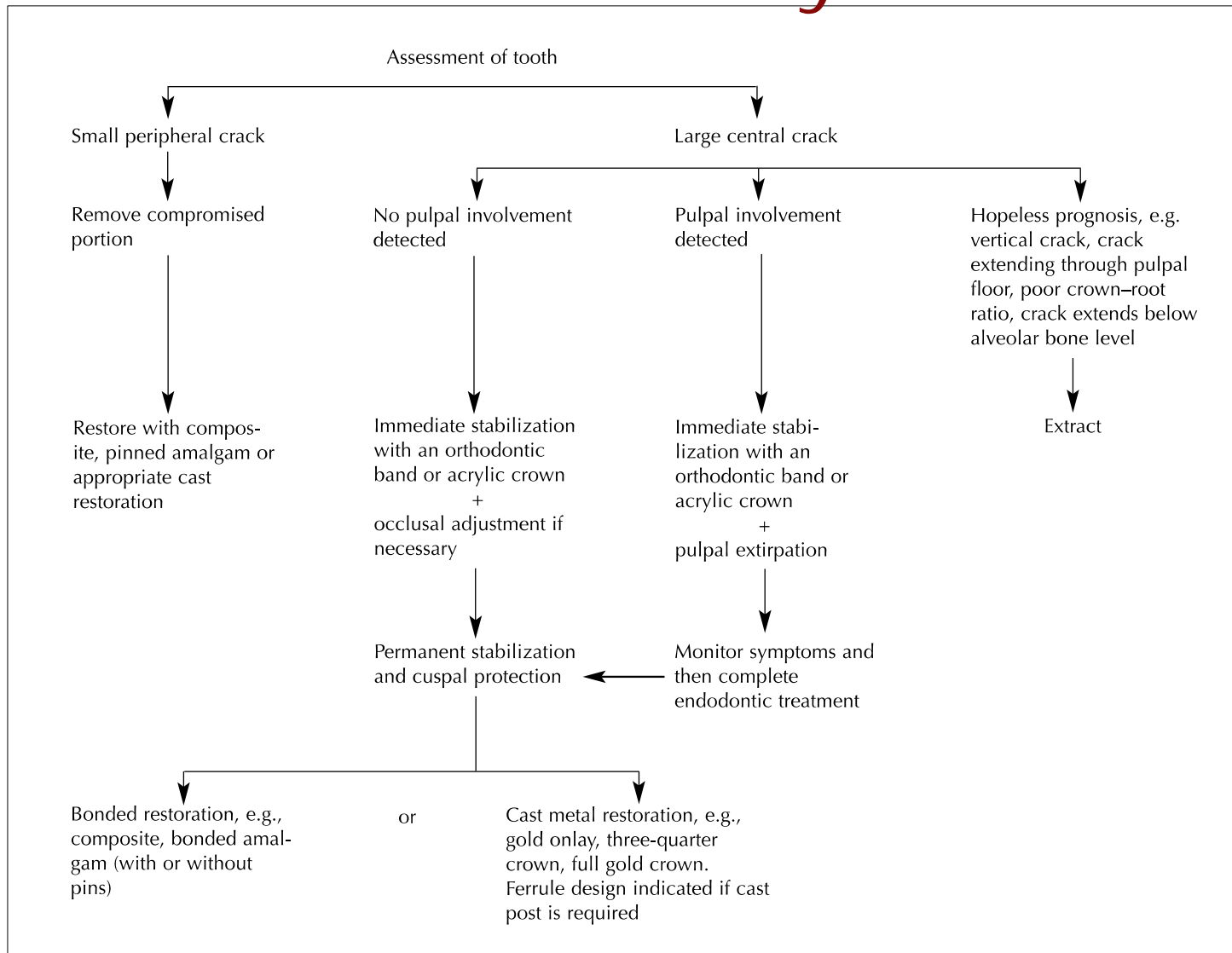
CRACKED TOOTH SYNDROME

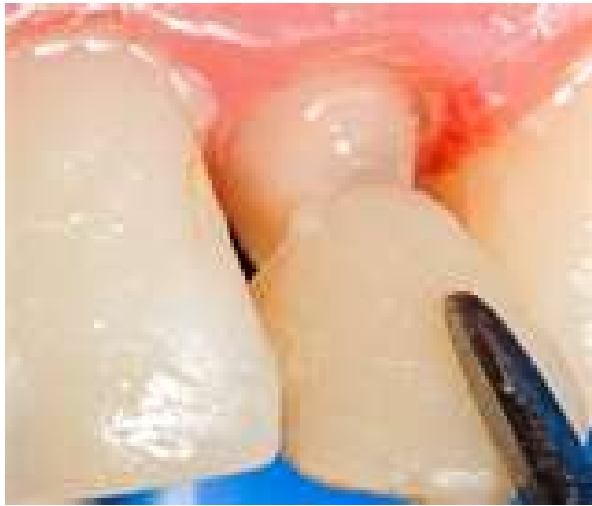
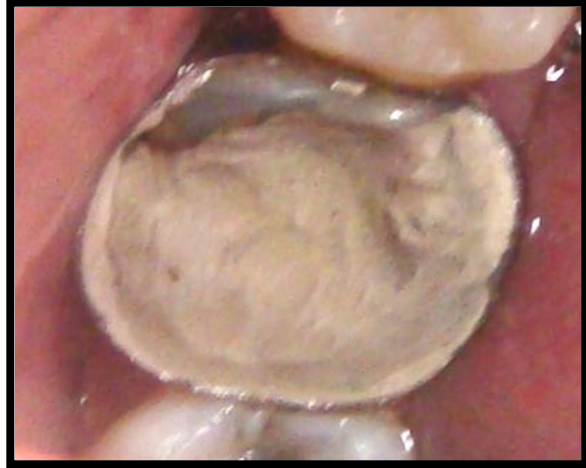
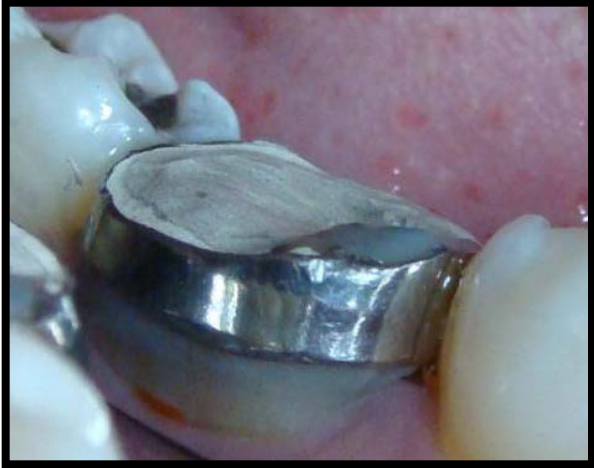CRACKED TOOTH SYNDROME



Cracked Tooth Syndrome





CROWN ROOT FRACTURE

ROOT FRACTURE

- Identify the level of fracture and restorability
- Initial tx- reposition segment
(*if displaced*)
- EPT-show high reading or absent
- Stabilization-→ splinting
- Finger pressure followed by ortho wire and acid etched resin
- Duration: 12 weeks

Root Fracture

- Root #heal spontaneous/ following splint therapy
- Characterised by development calcific metamorphosis (radiographic obliteration)
- X evidence of pulp necrosis-→ **NO RCT**
- **Prognosis:**
 - Coronal third: **poor**
 - Middle third: **moderate**
 - Apical third: **good**

INTERAPPOINTMENT

Flare-up

*...interappointment
emergencies (IAE) such as pain or
swelling which require nonscheduled
office visits and palliative
treatment...*

Factors associated with increased incidence of flare-ups:

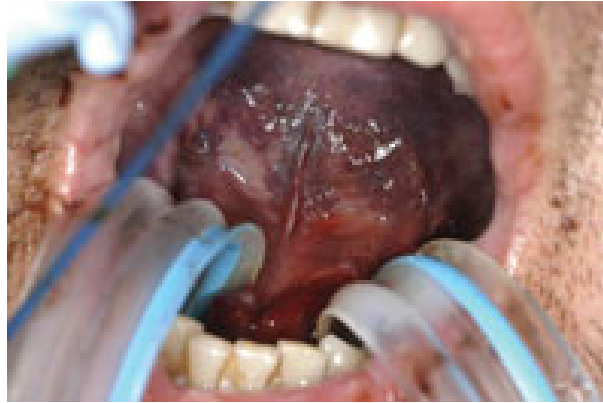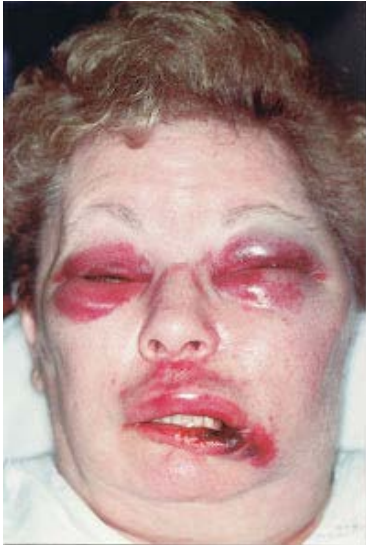- Age between 40 and 59
- Female
- Mandibular bicuspids
- History of allergies
- Preoperative complaints
- No or small periapical lesions
- Retreatment cases

Torabinejad et al.

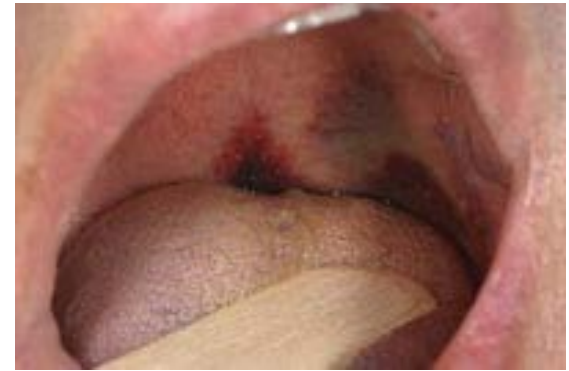INTERAPPOINTMENT

- Flare-ups- Causative factors
 - Overinstrumentation/extrusion/overfilling
 - Reconfirm WL
 - Perforation
 - Root fracture
 - Premature contacts at temporary restn

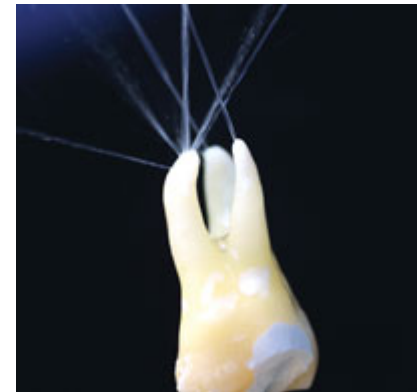

NaOCL ACCIDENT



mandibular region



Widespread diffusion of sodium hypochlorite into the soft palate.



Extrusion of irrigant through the open apical foramen

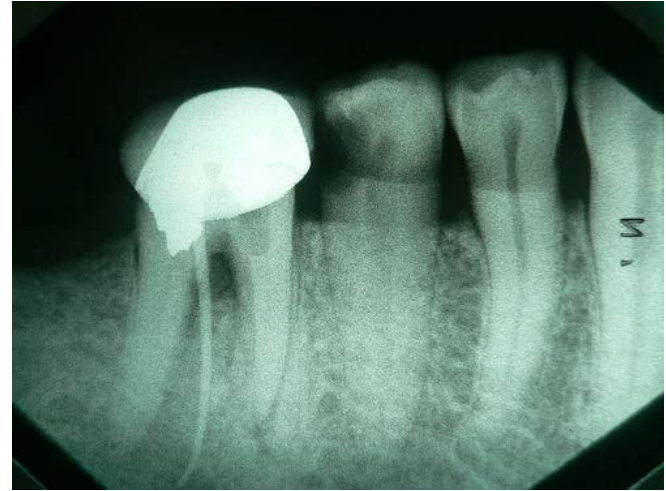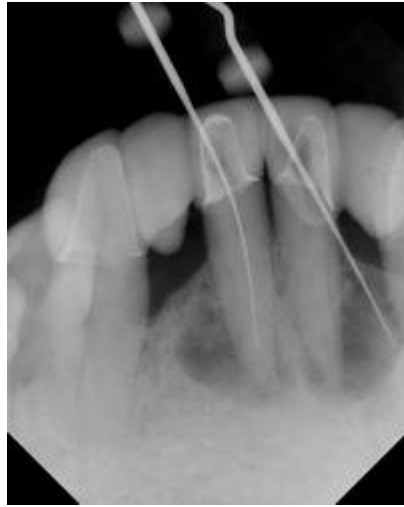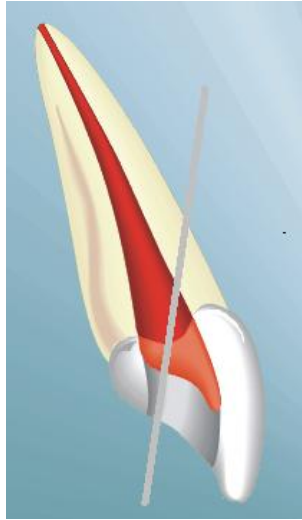Prevention

INTERAPPOINTMENT FLARE-UP

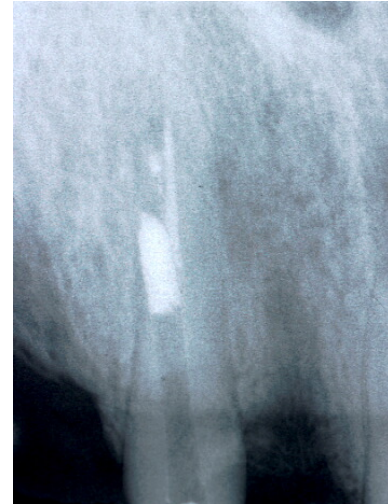
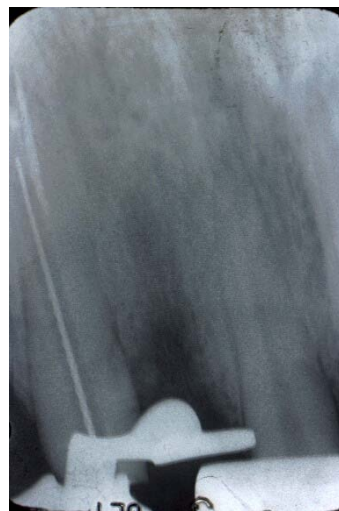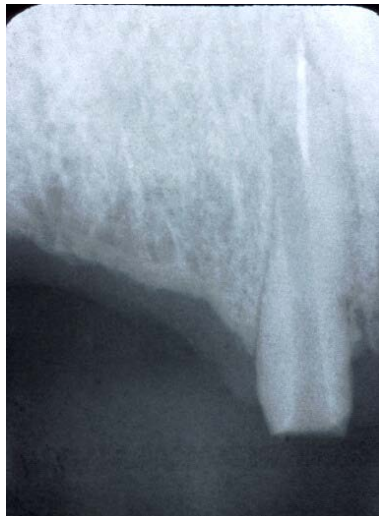- 4.2% incidence in 334 patients treated by undergraduate students
- Significantly higher in nonvital teeth

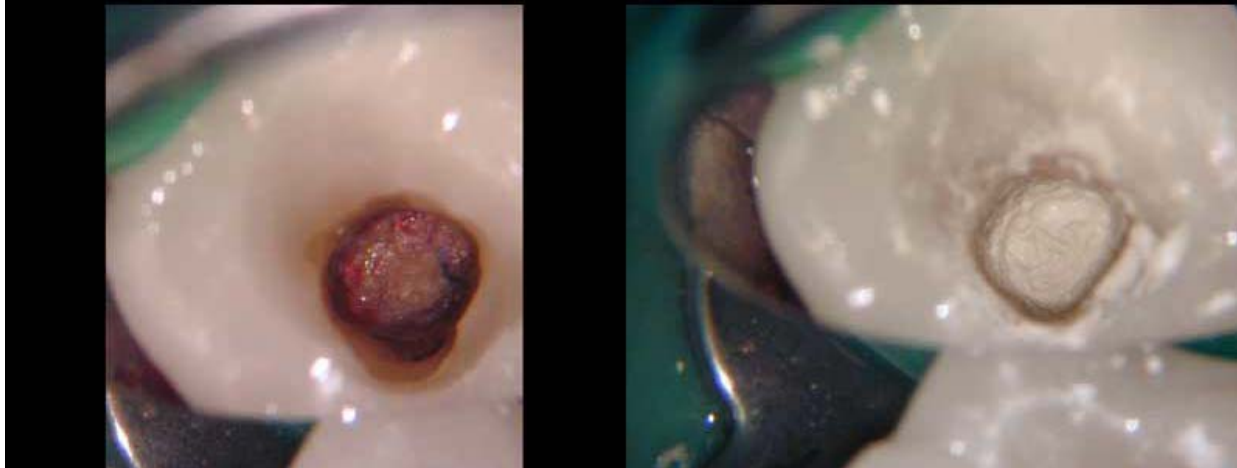
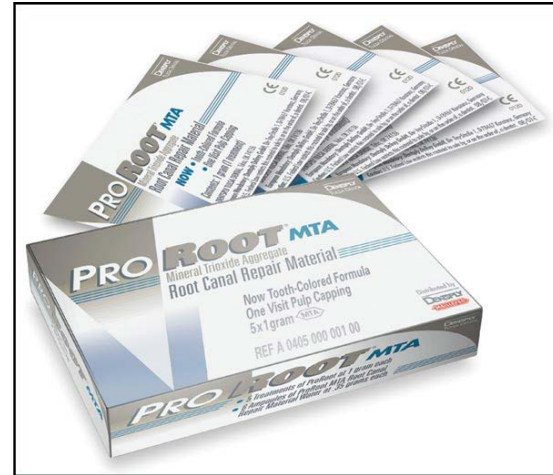
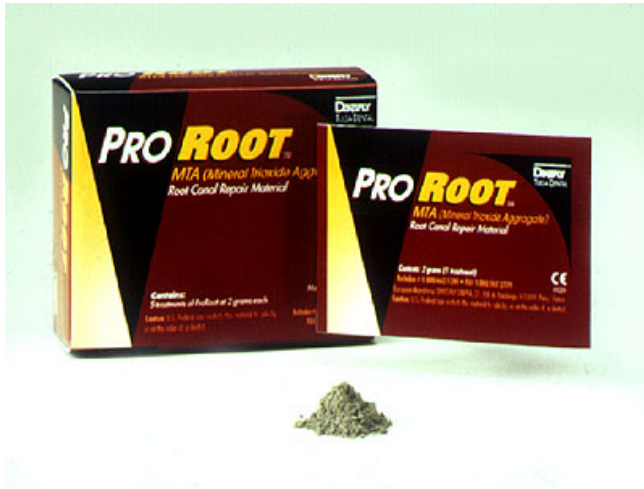Rotstein and Freidmand, 1992

PERFORATION



Mx

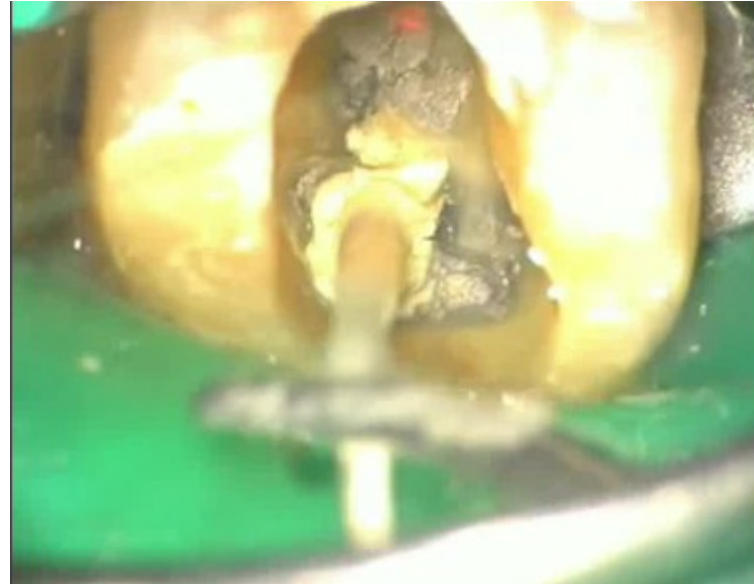




PERFORATION REPAIR

Perforation

- Application of MTA
- MTA Gun System (like amalgam plugger)
- 2 curve needle
- MTA endo manual carrier





Post Obturation

Post Obturation

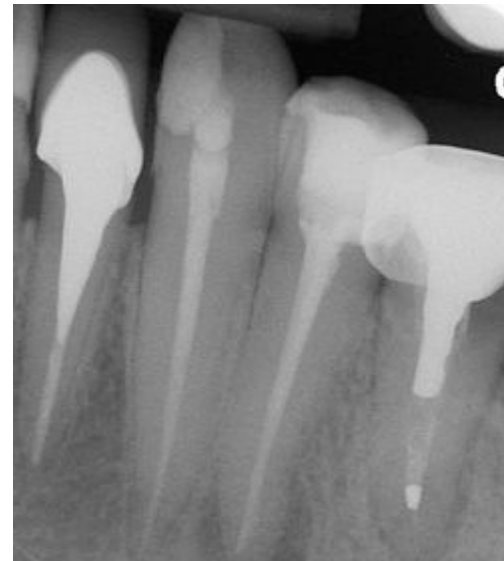
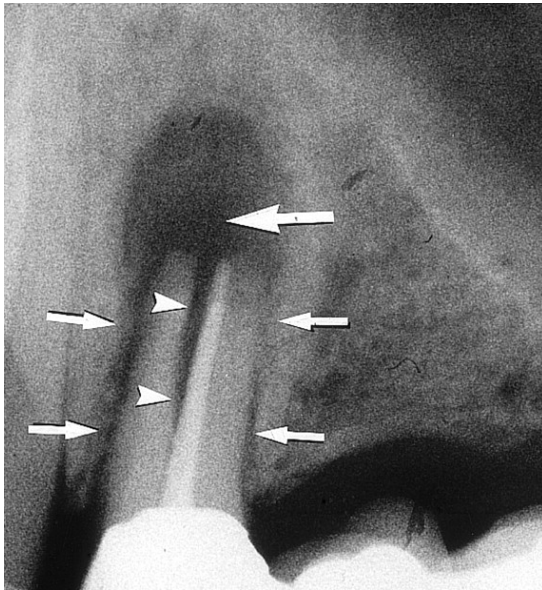
- Restoration- periodontal pain
- Root canal filing- overfiling/underfiling
- Vertical Root Fracture
- Lateral periodontal abscess, may involved adjacent tooth

Mx:

- Determine aetiology and diagnosis
- Treatment-Retreatment

Post Obturation

- Vertical Root Fracture
 - Bone lost from occlusal along the root
 - Post loose



Take Home Note

- Good knowledge and experience are important factors in managing emergency cases

REFERENCES

1. Pathways of Pulp- Cohen and Hangreaves
2. Principle And Practice Of Endodontics (A Saunders Core Textbook In Dentistry) -Walton and Torabinejad
3. Problem solving in Endodontic – 4 th edn Gutman
4. Mor C, Rotstein I, Freidman S. Incidence of interappointment emergency associated with endodontic treatment. JOE 1992



THANK YOU